

GENITOFEMORAL NERVE BLOCK AND INTRAOPERATIVE ANALGESIA IN CHILDREN DURING INGUINAL HERNIA REPAIR

NAILA ASAD, FARRUKH AFZAL, KHAWAR, ALI ASIF HANIF
HUMA SALEEM, AND SYED M. HUSSAIN

Department of Anaesthesiology, King Edward Medical University and Allied Hospitals, Lahore

ABSTRACT

Ilioinguinal and iliohypogastric nerve blocks has been widely used in children undergoing inguinal herniorrhaphy. This technique may provide insufficient intraoperative analgesia as the inguinal region may receive innervation from genitofemoral nerve. We proposed that the addition of genitofemoral nerve block might improve the quality of analgesia. The objective was to find the efficacy of genitofemoral nerve block in addition to ilioinguinal and iliohypogastric nerve block for better intraoperative pain management in children under going inguinal hernia repair under general anaesthesia. After informed consent, 100 children of 1-10 yrs of age and ASA I or II status undergoing inguinal hernia repair were selected and divided in group I and II of 50 patients each. After induction of general anaesthesia, Group I patients received ilioinguinal and iliohypogastric block using bupivacaine 0.375% at a dose of 0.75 mg/kg, where as patients in group II were given genitofemoral in addition to ilioinguinal and iliohypogastric nerve blocks using bupivacaine 0.375% at a dose of 0.375 mg/kg at each site. Changes in heart rate, systolic, diastolic and mean arterial pressures were recorded before the start of surgery, at skin incision, at sac traction and at the end of surgery as a measure of efficacy of the block. Haemodynamic data was analysed using repeated measures ANOVA. The two groups showed increase in (Heart Rate) but the increase was lesser in group II at sac traction ($p < 0.05$). In group I all patients had an increase in systolic, diastolic and mean arterial pressure at sac traction while the patients in group II showed no change during the study period ($p < 0.05$). We conclude that the addition of a genitofemoral nerve block to ilioinguinal and iliohypogastric nerve blocks may contribute to haemodynamic stability during sac traction indicating better pain relief.

Key words: *Ilioinguinal-iliohypogastric and genitofemoral nerve blocks, Intraoperative haemodynamics, intraoperative analgesia, children.*

INTRODUCTION

Inguinal hernia repair is one of the frequently performed surgical procedures in children.¹ Analgesia for this procedure includes opioids, non opioid analgesics, neuraxial blocks and regional nerve blocking techniques. Preoperative ilioinguinal and iliohypogastric blocks have been widely used to provide analgesia in children undergoing inguinal herniorrhaphy.² These methods are increasing in popularity as hernia repair is increasingly being performed as day care surgery. These nerve blocks are devoid of side effects and delay in discharge from day care surgery associated with opioids, NSAIDS, spinal and caudal blocks is avoided. As these blocks are administered before the surgical stimulus they may prevent an increase in excitability of central nervous stimulus and attenuate intraoperative and post operative pain according to the concept of preemptive analgesia.³ However it has been seen that this technique may prove insufficient to provide complete intraoperative management and must be supplemented by analgesics or other techniques.⁴ Inadequacy of block is especially evident during sac traction. One of the tech-

niques of improving the efficacy of ilioinguinal and iliohypogastric nerve block is to perform a genitofemoral nerve block simultaneously.⁵ Genitofemoral nerve has a variable course and innervation in the inguinal region. As a consequence inguinal canal may also receive innervation from genitofemoral nerve. Genitofemoral nerve entrapment neuralgia has been reported as a postoperative complication of inguinal hernia repair.^{2,5,6} Therefore we used addition of genitofemoral nerve block to ilioinguinal and iliohypogastric nerve blocks to improve the quality of pain control during surgery.

METHODS

This study was approved by the Anaesthesia Department and Ethics Committee of Mayo Hospital Lahore. After consultation with a biostatistician and informed parental consent, 100 children (aged 1-10 yrs and ASA I and II status) were selected in this prospective randomised, observer blinded study. Patients with bilateral or recur-

rent inguinal hernias, those who were allergic to local anaesthetics or those who required sedative premedication were excluded from the study. On arrival in the theatre IV line was maintained in all patients with ringer lactate. Monitoring instituted in all patients included ECG, pulse oximetry, end tidal carbon dioxide and non invasive blood pressure measurement. General anaesthesia was induced using injection thiopentone (5 mg/kg) and injection succinylcholine (1 mg/kg), followed by placement of appropriate sized endotracheal tube and was maintained with nitrous oxide (70%) and halothane (2%) in oxygen with spontaneous respiration. After induction of anaesthesia, patients were assigned to groups I & II. In group I, patients received ilioinguinal and iliohypogastric nerve block by injecting bupivacaine (0.375%) with a dose of 0.75 mg/kg into the area 2cm medial to the anterior superior iliac spine on the operative side. The injection was administered below the aponeurosis of external oblique muscle using a 25 guage needle. In group II patients received ilioinguinal and iliohypogastric and genitofemoral nerve blocks (Fig. 1). The ilioinguinal and iliohypogastric nerve block was given using the technique described above whereas genitofemoral nerve block was performed immediately proximal to the pubic tubercle on a line linking anterior superior iliac spine with pubic symphysis,

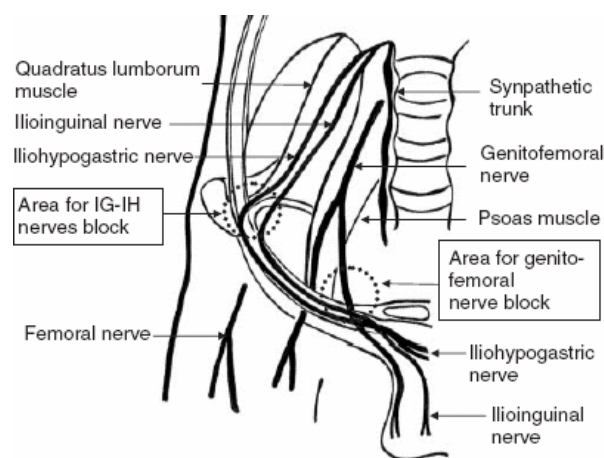


Fig. 1: Course of the ilioinguinal, iliohypogastric, and genitofemoral nerves. The circle indicates area infiltrated with local analgesic for each block. The centre of the circle (dotted line) indicates the point of insertion of the needle for each nerve block.²

Table 1: Patient characteristics, data presented as mean \pm SD.

| Variable | Group I (n = 50) | Group II (n = 50) | Total (n = 100) |
|-------------|------------------|-------------------|------------------|
| Age (years) | 5.56 \pm 2.71 | 5.23 \pm 2.91 | 5.39 \pm 2.80 |
| Weight (kg) | 16 \pm 5.42 | 14.66 \pm 6.13 | 15.33 \pm 5.80 |

below the aponeurosis of external oblique muscle. Bupivacaine (0.375%), 0.375 mg/ kg was given at each site. Heart rate (HR), systolic (SBP), diastolic (DBP) and mean arterial pressure (MAP) were recorded before the start of surgery (control 1), at skin incision,² at sac traction³ and at the end of surgery.⁴ Episodes of incidence of increase or decrease in heart rate and blood pressures were evaluated. Rescue analgesia was available in the form of nalbuphine (0.1 mg/kg) in case of inadequate pain control. Demographic data was analysed using student t test. Changes in haemodynamic variants were evaluated and analysed by repeated measure ANOVA. A p value <0.05 was taken as statistically significant.

RESULTS

The two groups were identical for age and weight (Table 1).

Heart rate before surgery (control) was similar in the two groups, 106 (15) 108 (8) beats / min, respectively. In both groups HR increased at sac traction (3) but in group I a significant increase was seen as compared to group II (p = 0.00) (Fig. 2).

Before surgery, SBP values in group I and II were 97 (10) and 103 (9) mmHg respectively. In group I, 40% patients showed no change in SBP at skin incision (2) while 40% showed a decrease and 20% had an increase in SBP. At sac traction (3), all patients in group I showed an increase in SBP while in Group II, no change was seen throughout the study period (p=0.00) (Fig. 3).

Before surgery, DBP values in group I & II were 59 (9.8) & 64 (10.7) mmHg respectively. In group I, 40% patients showed no change in DBP at skin incision (2) while 40% showed a decrease and 20% had an increase in DBP. In group I, at sac traction (3), all patients showed an increase in DBP while in Group II, no change was seen throughout the study period (p<0.05) (Fig. 4).

Before surgery, MAP values in group I & II were 73 (9) and 76 (10) mmHg respectively. In group I, 40% patients showed no change in MAP at skin incision (2) while 40% showed a decrease and 20% had an increase in MAP. In group I, at sac traction (3), all patients showed an increase in MAP while in Group II, no change was seen throughout the study period (p=0.00) (Fig. 5). Only two patients complained of vomiting post-operatively.

DISCUSSION

Importance of analgesia in children undergoing surgery can not be overemphasized. Inguinal hernia repair like any other surgery requires

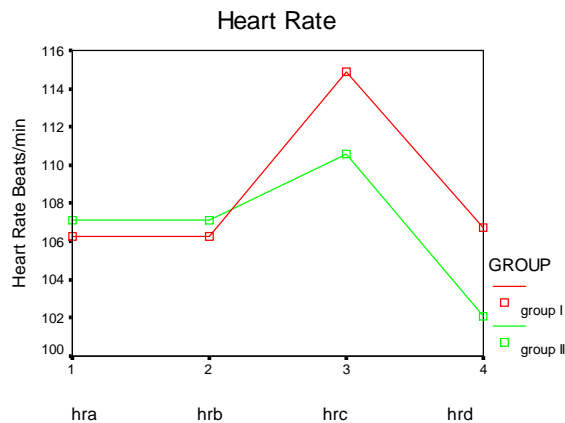


Fig.2: Mean Heart Rate at four points during study

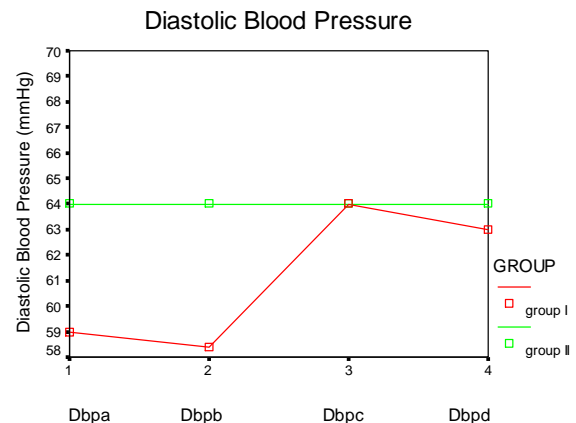


Fig.4: Mean Diastolic Blood Pressure at four points during study.

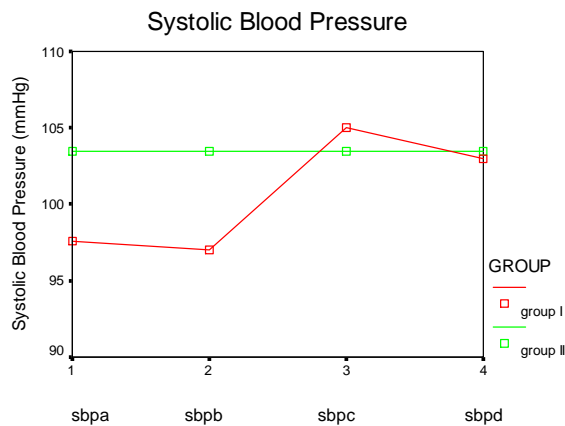


Fig.3: Mean Systolic Blood Pressure at four points during the study.

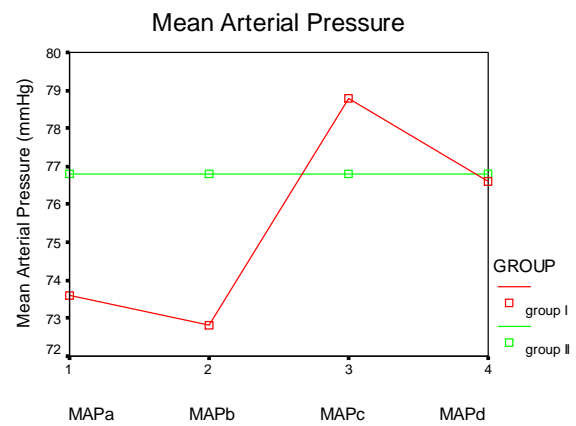


Fig.5: Mean Arterial Pressure at four points during study.

analgesia to provide optimal intraoperative conditions and adequate post operative pain relief. Regional analgesia for inguinal hernia repair in children has attracted increasing interest over the past few years. The use of supplemental regional anaesthesia not only decreases the requirement of general anaesthesia but also the need for post operative analgesia leading to early restoration of activity. Also it is associated with less complications and leads to an early discharge further proving its cost effectiveness. Blockade of ilioinguinal-iliohypogastric nerve can significantly reduce anaesthetic and analgesic requirement in both children and adults undergoing inguinal herniorrhaphy.⁷

Inguinal area has a variable innervation. It receives sensory fibers from ilioinguinal, iliohypogastric and genitofemoral nerve. The genital branch of genitofemoral nerve passes along psoas major and enters the internal oblique ring. In male subjects it descends behind the spermatic cord and supplies motor fibers to cremasteric muscle and sensory fibers to a part of the scrotal skin. In female subjects, it accompanies round ligament and supplies partial

sensation to the skin of mons pubis and labium major. However previously published studies showed great variation in the innervation of inguinal region with free communication between the branches of these three nerves.⁶ Starling et al conducted a study using genitofemoral neurectomy for chronic pain management after inguinal herniorrhaphy.⁸ Therefore in our study we considered that incomplete effect of ilioinguinal-iliohypogastric blockade seen in some patients may be due to contribution of genitofemoral nerve to the innervation of this area.

This study shows that addition of genitofemoral nerve block to ilioinguinal, iliohypogastric nerve block significantly reduced the incidence and extent of increase in heart rate and blood pressure intraoperatively. The results of heart rate in our study were the same in comparison to previous study done by Sasoka et al.² In group I, HR increased from 4-10% in our patients while in group II, it remained the same at skin incision but the slight increase (2%) at sac traction was seen which was less than group I.

At skin incision 40% of our patients showed a 2% decrease and 20% showed an increase of 2% in SBP, DBP, MAP in group I, whereas the blood pressure remained the same in group I in the study of Sasoka et al. This difference could be due to variation in concentration of bupivacaine. At sac traction all our patients in group I showed an increase of 5-10% which were similar to the results by Sasoka et al.² In group II, our results supported the study by Sasoka et al as no change in SBP, DBP and MAP was seen throughout study period. The benefit of genitofemoral nerve block was seen at the time of sac traction. An additional intraoperative benefit of ilioinguinal and genitofemoral nerve block seen was the use of lower concentration of halothane. None of the adverse effects of genitofemoral nerve block was seen.

The success of our study compares well with other studies in terms of intraoperative haemodynamic stability. Studies have shown the success of nerve stimulator guided paravertebral block to ilioinguinal for analgesia in children after inguinal herniorrhaphy. The study by Naja et al showed better intraoperative haemodynamic stability and significant decreased need for postoperative analgesia in children treated with nerve stimulator guided paravertebral block.⁹ Their results were similar with our study showing an increase in haemodynamics at sac traction with ilioinguinal block. The difference in our study was that we added genitofemoral nerve block instead of paravertebral block and found it to be effective in maintaining intraoperative haemodynamic stability.

Our study does not assess the adequacy of the blocks postoperatively where supplementation may have been required for adequate analgesia. Further studies can be performed to assess the adequacy of these blocks for postoperative pain.

It is **concluded** that the addition of a genitofemoral nerve block attenuated the haemodynamic responses at sac traction, suggesting its involvement in nociceptive input during inguinal hernia repair.

ACKNOWLEDGEMENTS

The authors are thankful to the Vice Chancellor of KEMU and M.S of Mayo Hospital and the Ethical Committee of KEMU for allowing us to publish is article.

REFERENCES

1. Machotta A, Risse A, Bercker S et al. Comparison between instillation of bupivacaine versus caudal analgesia for postoperative analgesia following inguinal herniotomy in children. *Paediatr Anaesth* 2003; 13: 397-402.
2. Sasoka N, Kawaguchi M, Yoshitani K et al. Evaluation of genitofemoral nerve block, in addition to ilioinguinal and iliohypogastric nerve block, during inguinal hernia repair in children. *Br J Anaesth* 2005; 94: 243-246.
3. Dahl JB, Kehlet H. The value of preemptive analgesia in the treatment of postoperative pain. *Br J Anaesth* 1993; 70: 434-439.
4. Yaster M, Maxwell LG. Paediatric regional anaesthesia. *Anaesthesiology* 1989; 70: 324-38.
5. Ala-Kokko TI, Karinen j, Raiha e, Kiviluoma K, Alahuhta S. Pharmacokinetics of 0.75% ropivacaine and 0.5% bupivacaine after ilioinguinal and iliohypogastric nerve block in children. *Br J Anaesth* 2002; 89: 438-41.
6. Rab M, Ebmer J, Dellon Al. Anatomic variability of the ilioinguinal and genitofemoral nerve: Implications for the treatment of groin pain. *Plast Reconstr Surg* 2001; 108: 1618-23.
7. Hinkle AJ. Percutaneous inguinal block for outpatient management of postherniorrhaphy pain in children. *Anesthesiology* 1987; 67: 411-13.
8. Starling JR, Haems BA. Diagnosis and treatment of genitofemoral and ilioinguinal neuralgia. *World J Surg* 1989; 13: 586-91.
9. Z.M. Naja, M. Raf, M. El. Rajab, N. Daoud, F.M. Zia-de, M. A. Al Tannir, and P.A. Lonqvist. A comparison of nerve stimulator guided paravertebral block and ilioinguinal nerve block for analgesia after inguinal herniorrhaphy in children. *Anaesthesia*, 2006; 61: 1064-68.